

Diagnostic update

Feline oral inflammatory disease – common clinical findings, diagnostic pathways and therapy

Introduction

Oral disease in cats is frequently observed during routine clinical examination. In cats, the most common chronic lesions are of either inflammatory or neoplastic nature. With oral neoplasia mostly being malignant in the domestic cat,¹ this is an important distinction to be considered.

Oral inflammatory conditions can have various causes, and a specific diagnosis is essential for planning appropriate treatment and assessing prognosis. This will help support the management not only of the patient but also of pet owner expectations.

Feline chronic gingivostomatitis (FCGS) is one of the most important oral inflammatory conditions in cats and a common challenge when caring for feline patients.

What to expect in this update:

- + Clinical signs of FCGS
- + Role of FHV-1 and FCV
- + Detection of FHV-1 and FCV (and diagnosis of FCGS: test code HISTFPE)
- + Implications of viral infections for therapy

Feline chronic gingivostomatitis (FCGS)

FCGS has been known by various synonyms like lymphoplasmacytic stomatitis, lymphoplasmacytic gingivitis stomatitis complex, plasmacytic stomatitis or caudal stomatitis.

FCGS is a specific entity of a severe oral mucosal inflammatory disease of cats with a prevalence ranging from 0.7% to 12% in the cat population in the US and Europe.² An inappropriate immune response to antigenic stimulation (immune-mediated disease) is suspected, potentiated or exacerbated by viral infection, including feline calicivirus (FCV),^{3,4} feline herpesvirus (FHV-1),⁴ feline immunodeficiency virus (FIV) and feline leukemia virus (FeLV). Because of the **latency and carrier status** of FHV-1 and FCV, testing for these as well as for FeLV and FIV as potential immunosuppressive agents will help with treatment planning and management.

Non-infectious agents incriminated are environmental stressors (multicat environment and outdoor access), hypersensitivity and/or dental diseases (e.g. plaque, periodontitis, tooth resorption or alveolar bone loss).

Clinical presentation of FCGS

FCGS causes bilateral symmetrical ulcerative and/or proliferative inflammatory lesions.

- + Characteristically affected areas are caudal oral area, alveolar mucosa, labio-buccal mucosa and cheek mucosa, lateral palatoglossal folds and lingual mucosa.⁵ Classical clinical presentations will show inflammation crossing the mucogingival junction and variable extends into buccal and caudal oral mucosa (figures 1 and 2). Extension into the esophagus can also be observed.⁶ Associated lesions include localized to generalized periodontitis, alveolar bone loss (in particular horizontal bone loss), external inflammatory root resorption and retained roots.⁷
- + Dental radiography may reveal lesions of hard tissues of the dentoalveolar complex, which includes exacerbation of concurrent periodontitis and involvement of alveolar bone and teeth including the roots.⁸
- + Associated clinical signs are oral pain, halitosis, ptyalism, lack of grooming, weight loss, dysphagia/anorexia and/or behavioural changes.
- + Clinical differential diagnoses to be ruled out are listed in figure 3.

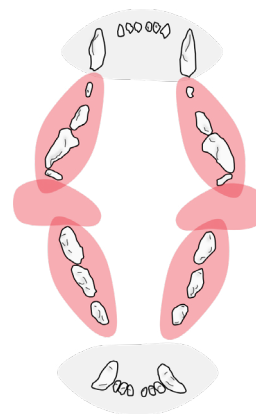


Figure 1. The classically affected sites in the oral cavity of the cat with FCGS (highlighted in red)

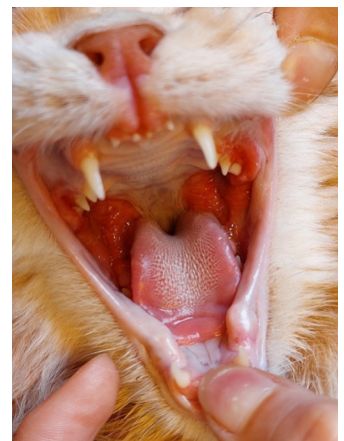


Figure 2. FCGS, clinical example: extensive swollen (proliferative) inflammatory lesions of the caudal oral mucosa.

Figure 3. Other clinical differential diagnoses of FCGS (ulcerative or proliferative/stomatitis/gingivitis).

Infectious inflammatory diseases	Non-infectious inflammatory diseases	Non-neoplastic oral masses	Neoplastic oral masses
Bacterial infections (secondary to inflammation, trauma, foreign body, neoplasia)	Eosinophilic granuloma	Fibromatous epulis of periodontal ligament origin (also known as peripheral odontogenic fibroma, nomenclature according to current international histologic classification of tumours of domestic animals)	Squamous cell carcinoma
Fungal disease (very rare)	Granulomatous stomatitis (due to foreign body material or local trauma)	Alveolar bone expansion and osteomyelitis	Fibrosarcoma
	Uremia-associated stomatitis		Melanoma
	Juvenile gingivitis (around tooth eruption), juvenile hyperplastic gingivitis and juvenile periodontitis		Lymphoma

Radiographs and recommended diagnostic steps

- + Changes of the hard tissues of the dentoalveolar complex do not only occur in neoplastic disease but are also occasionally seen in FCGS.
- + Therefore, full-mouth dental radiography is an essential part of the diagnostic workup.
- + Radiographs should be made first, followed by biopsies from representative lesions.
- + The pathologist should be provided with a precise history that includes sample location in regard to oral anatomy and representative changes on the dental radiographs.

Role of feline calicivirus and herpesvirus

Feline calicivirus (FCV)

- + FCV has been implicated in the pathogenesis of chronic oral disease, and FCV is shed from cats with chronic inflammation of the gingiva and oral mucosa. Classic presentations will show acute oral and upper respiratory signs with mucosal ulcerations of the tongue in particular, but FCV can also cause diverse and severe systemic signs that include shifting lameness and fever as well as cutaneous edema and ulcerative lesions on skin and paws depending on the strain involved. Once infected, **intermittent or chronic shedding** can be especially problematic in **multicat** households.

Feline herpesvirus (FHV-1)

- + FHV-1 is commonly associated with rhinotracheitis in cats and linked with many other signs, including ophthalmologic signs (conjunctivitis, keratitis, corneal ulceration, etc.), pharyngitis, ulcerative glossitis and palatitis, facial dermatitis, abortion and neonatal death.
- + After a mild or asymptomatic primary phase, FHV-1 typically presents with **latent phase that can be interrupted by periods of viral shedding.**

Infection with FCV and FHV-1 is more common in cats with FCGS than in cats with classical periodontal disease.

FCV and FHV-1 show intermittent or chronic shedding of viral particles, causing increased risk of infection and oral inflammatory changes in multicat households.

Diagnosis

Clinical presentation in characteristically affected areas in combination with histologic findings confirm the diagnosis of FCGS. The new IDEXX oral profile for cats (**test code: HISTFPE**) includes the following important tests:

- + Detection of presence of FCV and FHV-1 from affected area, which may influence the therapeutic approach and prognosis. In case of viral infection immuno-suppressing medication is not indicated.
- + Histological examination of affected oral location (similar location as used for the PCR swab), thereby confirming FCGS and excluding differential diagnosis.
 - + Histologically FCGS is characterized by erosion or ulceration and in the subepithelial stroma mainly plasma cells and fewer lymphocytes, with variable numbers of Mott cells.

Diagnosing FCGS using the new IDEXX test profile **HISTFPE** From **same** affected **location**:

- + Swabs for PCR of FCV and FHV-1 (the PCR of the profile HISTFPE is not possible from the tissue samples for the histopathologic examination, so swabs are mandatory)
 - + Determine presence of viral infection (which will affect therapy)
- + Biopsy for histopathological examination (figure 4)

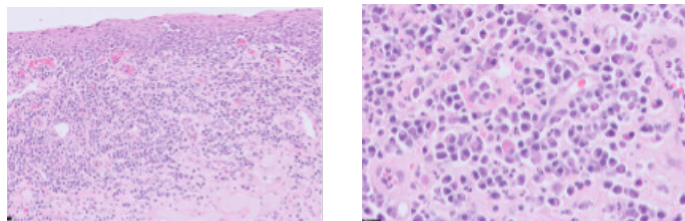


Figure 4. Histological findings: in the subepithelial stroma (left) an extensive chronic inflammation, consistent of mainly plasma cells mixed with low numbers of Mott cells.

Therapeutic approaches

Therapeutic approach of FCGS is challenging and **always individual**. Hence a full assessment of all etiologic factors involved will help with planning specific treatment for the individual patient.

Below an overview of the procedures described in the current literature.⁹ It is important to acknowledge that, in general, the treatment will need a long-term approach, and it can be challenging to achieve complete remission. Surgical treatment is the current standard since medical treatment alone typically has shown significantly less favorable long-term outcomes. Follow-up with medical therapies after surgical treatments have been performed and might be beneficial as well and support better outcomes. Clinical trials addressing this systematically are still lacking.

- + **Pain assessment and appropriate initiation of analgesic treatment should be the first step.** Treatment decisions will be depending on the severity of pain and possible concomitant diseases. Usually, a multimodal approach is indicated as, for example, NSAIDs will not be sufficient as a single agent treatment in most cases. Although administering analgesic treatment pre/peri-operatively has not shown significant influence on outcomes, it is mandatory.^{10,11}
- + **Surgical treatment** with either full-mouth extraction that includes canines and incisors or partial-mouth extraction of premolar and molar teeth and of other teeth with lesions like periodontitis, retained tooth roots, or resorptive lesions. The decision between these approaches will depend on the severity and localization of inflammation and may be taken stepwise with an intermittent period to allow assessment of healing. Substantial improvement or resolution of FCGS after surgical treatment is reported in 70%–80% of cats.
- + **Medical management** might be required in addition to surgical treatment, in some cases lifelong.
 - + Corticosteroids are often used to control inflammation over a short time.
 - + Interferons (IFN) interfere with viral replication and possess antiviral activity against FCV and FHV-1 among others. Recombinant feline interferon omega (rFeIFN- ω) has been shown effective after oro-mucosal absorption.
 - + Cyclosporine has immunosuppressive effects, and oral therapy has shown clinical remission and significant clinical improvement also in long-term observations.
 - + Antibiotic administration, according to sensitivity test, can be indicated in some cases and in context of tooth extraction. Antibiotics themselves have no significant therapeutical impact on FCGS.
- + **Environmental management**, especially reduction of stress, should be addressed; multicat households need to be investigated particularly.

References

1. Cray M, Selmic LE, Ruple A. Demographics of dogs and cats with oral tumors presenting to teaching hospitals: 1996-2017. *J Vet Sci.* 2020;21(5):e70. doi:10.4142/jvs.2020.21.e70
2. Thomas S, Lappin DF, Spears J, Bennett D, Nile C, Riggio MP. Prevalence of feline calicivirus in cats with odontoclastic resorptive lesions and chronic gingivostomatitis. *Res Vet Sci.* 2017;111:124–126. doi:10.1016/j.rvsc.2017.02.004
3. Nakanishi H, Furuya M, Soma T, et al. Prevalence of microorganisms associated with feline gingivostomatitis. *J Feline Med Surg.* 2019;21(2):103–108. doi:10.1177/1098612X18761274
4. Lommer MJ, Verstraete FJ. Concurrent oral shedding of feline calicivirus and feline herpesvirus 1 in cats with chronic gingivostomatitis. *Oral Microbiol Immunol.* 2003;18(2):131–134. doi:10.1034/j.1399-302x.2003.00033.x
5. Murphy BG, Bell CM, Soukup JW. *Veterinary Oral and Maxillofacial Pathology.* Wiley-Blackwell; 2020.
6. Kouki MI, Papadimitriou SA, Psalla D, Kolokotronis A, Rallis TS. Chronic gingivostomatitis with esophagitis in cats. *J Vet Intern Med.* 2017;31(6):1673–1679. doi:10.1111/jvim.14850
7. Farcas N, Lommer MJ, Kass PH, Verstraete FJ. Dental radiographic findings in cats with chronic gingivostomatitis (2002-2012). *JAVMA.* 2014;244(3):339–345. doi:10.2460/javma.244.3.339
8. Perry R, Tutt C. Periodontal disease in cats: back to basics—with an eye on the future. *J Feline Med Surg.* 2015;17(1):45–65. doi:10.1177/1098612X14560099
9. Lee DB, Verstraete FJM, Arzi B. An update on feline chronic gingivostomatitis. *Vet Clin North Am Small Anim Pract.* 2020;50(5):973–982. doi:10.1016/j.cvsm.2020.04.002
10. Monteiro BP, Steagall PV. Chronic pain in cats: Recent advances in clinical assessment. *J Feline Med Surg.* 2019;21(7):601–614. doi:10.1177/1098612X19856179
11. Steagall PV, Robertson S, Simon B, Warne LN, Shilo-Benjamini Y, Taylor S. 2022 ISFM consensus guidelines on the management of acute pain in cats. *J Feline Med Surg.* 2022;24(1):4–30. doi:10.1177/1098612X211066268