

Diagnostic update

Faecal Dx antigen testing – find parasite infections the microscope misses

Introduction

In order to ensure the health of patients, a faecal examination for intestinal parasites is an important part of a regular checkup. Regardless of the faecal procedure used, there can be some limitations on accurately identifying infections with some parasites. Detection of hookworm, roundworm, whipworm and flea tapeworm can be difficult with the current diagnostics. IDEXX Reference Laboratories offers Faecal Dx* antigen testing as an additional tool for detecting these common parasites.

Background

In small-animal practice, hookworms, roundworms, whipworms and flea tapeworms are commonly encountered intestinal parasites in canine and feline patients. They each have a unique life cycle, and their prepatent period, the time in which they infect a host before laying eggs, may range from 2–4 weeks in hookworms (2–3 weeks for *Ancylostoma caninum* and 3–4 weeks for *Uncinaria stenocephala*), variable in roundworms depending on infection route (typically 16–21 days after prenatal infection, 27–35 days after lactogenic infection and 32–39 days after ingestion of eggs), 2–3 weeks in flea tapeworms, to at least 8 weeks in whipworms.^{1,2} This prepatent period may allow infections to go undetected on faecal flotation, increasing the chance for the appearance of clinical signs prior to evidence of eggs or proglottids in the stool.^{3,4}

Prevalence and risk factors

In dogs and cats, the prevalence of infection with each intestinal parasite varies from region to region and tends to occur more frequently in shelter animals than in well-cared-for dogs and cats that visit the veterinarian on a regular basis. Outdoor pets and those that consume prey with possible infective larvae in their tissues may be more likely to be infected.

Faecal specimens of dogs visiting parks in 33 cities across 12 European countries were examined using a coproantigen diagnostic immunoassay and microscopy following centrifugal flotation. For nematode infection, 7.6 % of all dogs tested positive, with roundworms being the most prevalent (3.6 %, varying from 0 to 10.8 % depending on the country). Hookworms and whipworms were detected in 3.2 % (1.2 to 4.9 %) and 2.3 % (0 to 9.1 %) of the dogs, respectively. Infection was most prevalent in dogs aged < 1 year and declined with increasing age. In selected countries with the highest proportion of owners responding that they had treated their dog within the previous 3 months showed lowest percentage of roundworm eggs and vice versa.⁵

Apparent parasite prevalence was higher in hunting/herding dogs in France as compared to pet dogs as well as in dogs living in the countryside compared to dogs living in city.⁶ Latter study found 11.3 % (48/425) of the cats to be infected with *Toxocara cati*, with significant correlations regarding age, presence of other animals (cat and/or dog) at home, living environment/lifestyle, food type and time since last treatment.

The contaminated soil in kennels increased the infestation rate with whipworms in breeding dogs in selected European countries (i.e. Germany, Denmark, Switzerland, France) up to 14.5 %, and even in dog kennels with strict hygienic measures in the Netherlands, almost 5 % of dogs still shed *Trichuris vulpis*. Between 1% and 47.6 % of shelter dogs in selected European countries harbored a whipworm infection.⁷

Interesting observation for *Toxocara canis* in dogs on a long-term base was made in a study in Holland, revealing an overall prevalence of 4.5 %, resulting in an estimated average incidence of 0.54 patent infections per dog per year.⁸ No infections were diagnosed in 67.9 % of the dogs, 17.5 % of the dogs harbored it only once and 14.6 % had reinfections (up to nine times). The latter dogs were responsible for 72 % of the positive results. Prevalence always peaked during wintertime. Increased risks for first diagnosed infection with roundworms were associated with coprophagy, geophagy, walking off-leash for ≥ 80 % of walking time and others, while factors associated with increased reinfection risk were administration of corticosteroids or changing dog's main purpose.

Clinical signs

Some dogs and cats infected with these common intestinal parasites may show no clinical signs, but others may develop a variety of gastrointestinal signs that depend on the parasite and age of the patient. Signs may range from mild diarrhoea, vomiting and ill thrift to severe bloody diarrhoea, anaemia and occasionally death.⁹ Puppies carrying a heavy burden of roundworms may show more severe clinical signs, including pulmonary signs, intussusception and diarrhoea, and they may appear cachexic with a distended abdomen (pot-bellied appearance). They may vomit or shed worms within the feces.⁹

Considering hookworms, the virulence is different between *Ancylostoma* spp. and (especially for dogs) *U. stenocephala*. The erythrocyte uptake as a direct cause of anaemia is not a feature of *Uncinaria*, as well as dark, tarry diarrhoea, respiratory disease and foot lesions.¹⁰ In respect to *Uncinaria*, which is the most common hookworm in Europe and the only one in Central-Northern Europe, the clinical signs encompass ill thrift,

failure to gain weight, poor hair coat, mucous diarrhea (rarely bloody mucus) and hypoproteinemia with slight eosinophilia. *Ancylostoma tubaeforme* in cats can be similar to *A. caninum* in terms of blood loss. Many infections with whipworms can be subclinical without apparent clinical signs. When present, clinical signs include typically a large-intestine diarrhea streaked with mucus and fresh blood, weight loss, dehydration, anaemia, hypoalbuminemia and the so-called pseudo-Addison disease. This can be explained by the fact that whipworms are composed of a thin, filamentous anterior end, which is burrowed within the gut mucosa, and at an infection rate around 200 worms, a severe hemorrhagic inflammation within the large intestine (caecum and colon) takes place.⁹⁻¹¹

Dogs and cats with flea tapeworm infections rarely develop any clinical signs until they are present in large numbers. In cases with severe infection and in young animals, neurological signs, unspecific abdominal signs with ill thrift and pot-bellied appearance, but also intestinal pleating and obstructions (the worm length can reach up to 70 cm), are possible.^{2,10} The passage of the proglottids may cause perianal irritation.⁹

Current diagnostics

Currently, the most common method for diagnosing intestinal parasite infections is faecal flotation, either passive or by centrifugation. There are many issues that may complicate the diagnosis of infections with this method. One possible complication is misidentification. Pollen and other debris may be misidentified as eggs. In addition, the inappropriate identification of eggs from other species as a result of coprophagy (the ingestion of infected feces) may also occur. One study researching this occurrence found that 31.5 % *Toxocara*-positive canine faecal specimens were in fact *T. cati* eggs (molecular differentiation of the eggs), and another study found that a total of up to 50 % of *Toxocara* eggs in dog feces are intestinal passers (as determined by repeated examinations).^{12,13}

Another common problem concerns the varying density of the different eggs, which makes it difficult for a clinician to select the ideal faecal flotation solution to ensure adequate recovery of eggs from all potential parasites.¹⁴

Yet another challenge with faecal flotation is that this method of egg identification lacks the ability to detect infections during the prepatent period or with single-sex infections, when eggs are simply not present in the infected animal.¹⁵

Finally, faecal flotation may not always be reliable as a single test. Because some parasites can shed eggs intermittently, as has been observed with hookworms in dogs and cats, a specimen from an infected animal may still generate a false-negative diagnosis if only a single faecal flotation is examined.^{13,16}

For all these reasons, there is a need to find a better tool for the diagnosis of the most common intestinal parasites found in dogs and cats.

Testing innovations from IDEXX Reference Laboratories

Antigen detection is commonly used to diagnose heartworm (*Dirofilaria immitis*) and French heartworm (*Angiostrongylus vasorum*) in blood specimens and *Giardia* or *Cryptosporidium* infections in faecal specimens, and it is also available for these additional parasites. IDEXX Reference Laboratories has developed Faecal Dx* antigen testing, which includes immunoassays for the detection of hookworm, roundworm, whipworm and flea tapeworm antigens in feces. These antigens are secreted by the worm stages after infection and are not present in their eggs, which allows for detection of prepatent stages as well as the ability to overcome the challenges of intermittent egg shedding and detection of eggs resulting from coprophagy and only transiting the intestines. Early detection during the prepatent period will also reduce the frequency of environmental contamination with potentially infectious eggs. The European Scientific Counsel Companion Animal Parasites (ESCCAP) guideline 1 (GL1), *Worm Control in Dogs and Cats*, lists two options for the diagnosis of intestinal worms (roundworms: *T. canis*, *T. cati* and *Toxascaris leonina*; hookworms: *A. caninum*, *A. tubaeforme* and *U. stenocephala*; and whipworms: *T. vulpis*): centrifugal flotation and antigen test (table 6: worm infection of dogs: main clinical signs and diagnosis).¹ The new ESCCAP guideline 4 (GL4), *Parasitological Diagnosis in Cats, Dogs and Equines*, concludes that negative results of coproscopical methods should be interpreted with care due to their limited sensitivity, based on e.g. prepatency.³ Parasite stages (e.g. eggs) might not be detected in feces despite ongoing prepatent infection with clinical signs. This scenario can typically occur with whipworm infection.¹⁷ In these cases, the above mentioned guideline recommends further examination with alternative methods (i.e. antigen detection).³ Furthermore, antigen detection, which is commercially available for some canine nematode species (table 3 of GL4 lists the Faecal Dx* and PetChek* tests), increases the specificity by circumventing false-positive results of coproscopical methods due to coprophagy (e.g. *T. cati* eggs in dog feces after ingestion of cat excretions).³ In summary, antigen tests offer an increase in sensitivity and specificity by detection of prepatent infection and demasking coprophagy, respectively.⁴

Detect more infections – nematodes

A retrospective sample of intestinal parasite panels submitted to IDEXX Laboratories from 1,236,448 individual dogs coming from wellness visits (visits to the veterinarian for the purpose of annual exams, vaccinations, or routine checkups) were selected from 1 January 2017 to 31 December 2019 and were analyzed for positive nematode results. These data contain results from faecal exams performed using zinc sulfate flotation by centrifugation paired with coproantigen immunoassay results for hookworms, roundworms and whipworms (Faecal Dx antigen testing).¹⁸

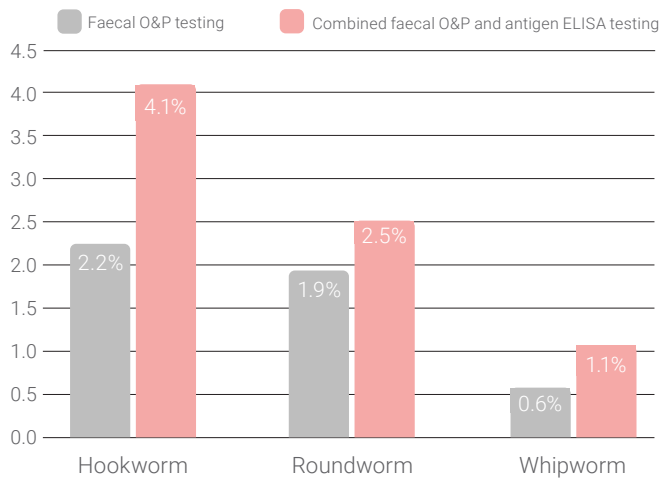
Hookworm eggs were detected in 2.2 % of the specimens. The hookworm-specific antigen ELISA was positive in an additional 1.9 % of specimens that were negative for hookworm eggs, thus

bringing the total hookworm detection with the combined faecal O&P and antigen ELISA testing to 4.1 %.

Roundworm eggs were detected in 1.9 % of the specimens. The roundworm-specific antigen ELISA was positive in an additional 0.6 % of specimens that were negative for roundworm eggs, thus bringing the total roundworm detection with the combined faecal O&P and antigen ELISA testing to 2.5 %.

Whipworm eggs were detected in 0.6 % of the canine specimens. The whipworm-specific antigen ELISA was positive in an additional 0.5 % of specimens that were negative for whipworm eggs by faecal O&P testing, thus bringing the total whipworm detection with the combined faecal O&P and antigen ELISA testing to 1.1 %.

Intestinal parasite detection



Detect more infections – cestodes

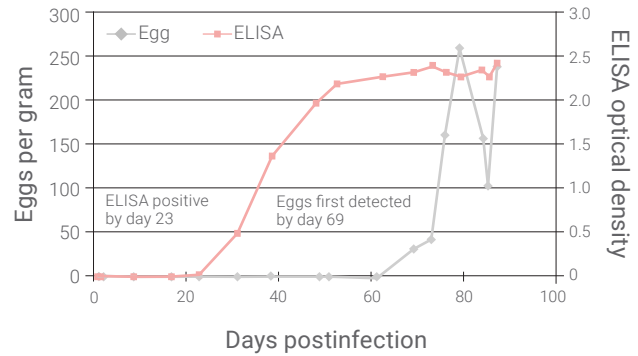
Studies have previously demonstrated that PCR can detect *Dipylidium caninum* in anal swabs or feces from experimentally infected and field dogs.^{19,20} In a study using experimentally infected dogs, 88 % of the specimens that were PCR positive were also positive for flea tapeworm by coproantigen immunoassay.²¹ In a field study of dogs infested with fleas, positive and negative agreement between *D. caninum* PCR and coproantigen detection was 77 % and 97 %, respectively.²¹ Analysis of 893 specimens submitted to IDEXX Reference Laboratories detected flea tapeworm antigen in 5.8 % of the specimens while only 2 (0.22 %) were positive on faecal flotation by centrifugation (faecal O&P).²²

Detect infections earlier

Because of the lack of egg detection with faecal O&P testing during the prepatent period, single-sex infections or intermittent egg shedding, many parasite infections may go undetected for a period of time and, therefore, create a difficulty in correlating clinical signs to faecal test results. In experimental infection studies with antigen tests conducted at IDEXX, the faecal antigen ELISAs were able to detect infection during this prepatent stage in cats and dogs.^{16,23,24}

The graph below illustrates the identification of a whipworm infection more than 30 days before faecal O&P testing when using the whipworm-specific antigen ELISA.²⁴

Prepatent infection detection (whipworm experimental model)



Treatment

There are a variety of anthelmintic products available for both treatment and control of intestinal parasite infections. Please see the current ESCCAP recommendations for guidance^{1,9} and esccap.org for links to therapy tables by country or region.

Faecal Dx* antigen testing detects worm antigen. A positive antigen test indicates infection. Antigen-positive and egg-negative specimens can be seen during the prepatent period, with single-sex infections, and as a result of intermittent egg shedding. Microscopic identification of eggs in antigen-negative specimens may be due to coprophagy or because the amount of antigen is below the level of detection. Treatment should be considered for patients found positive by antigen, egg or proglottid detection.

Public health considerations and preventive measures

Because of the zoonotic potential of these parasites, most commonly hookworm and roundworm, immediate disposal of feces is important. This will also reduce the likelihood of reinfections and prevent the long-term contamination of the environment. Monthly anthelmintic medications can be required sometimes in preventing the continuation of the cycle. ESCCAP provides schemes for individual risk assessment and medication of dogs and cats.¹ The routine treatment and prevention of all worms depends upon legislation in individual countries, veterinary professionals taking local epidemiological circumstances into account, owner perception and individual risk assessments, i.e. hunting pets, previous parasite exposure, raw meat diets, etc. Therefore, medication practices should always be on the advice of a veterinary professional.

Contacting IDEXX

Laboratory Customer Support

If you have any questions regarding test codes, turnaround time, or pricing, please contact our Laboratory Customer Support Team.

Expert feedback when you need it

Our medical specialty consulting service is available for expert and complimentary consultation.

Recommended reading

Elsemore DA, Geng J, Flynn L, Cruthers L, Lucio-Forster A, Bowman DD. Enzyme-linked immunosorbent assay for coproantigen detection of *Trichuris vulpis* in dogs. *J Vet Diagn Invest*. 2014;26(3):404–411. doi:10.1177/1040638714528500

References

1. ESCCAP Guideline 01 Sixth Edition – May 2021: Worm Control in Dogs and Cats. European Scientific Counsel Companion Animal Parasites; 2021. Accessed February 8, 2023. www.esccap.org/uploads/docs/oc1bt50t_0778_ESCCAP_GL1_v15_1p.pdf
2. Rousseau J, Castro A, Novo T, Maia C. *Dipylidium caninum* in the twenty-first century: epidemiological studies and reported cases in companion animals and humans. *Parasit Vectors*. 2022;15(1):131. doi:10.1186/s13071-022-05243-5
3. ESCCAP Guideline 04 First Edition – November 2022: Parasitological Diagnosis in Cats, Dogs and Equines. European Scientific Counsel Companion Animal Parasites; 2022. Accessed February 8, 2023. www.esccap.org/uploads/docs/hgqo8xak_1335_ESCCAP_GL4_v2_1p.pdf
4. ESCCAP UK & Ireland. *Intestinal Nematodes: Ascarids, Hookworms and Whipworms: Considerations for Routine Diagnostic Screening*. European Scientific Counsel Companion Animal Parasites. Accessed February 8, 2023. www.esccapuk.org.uk/uploads/docs/veh93bk1_FINAL_Diagnostic_testing_poster.pdf
5. Drake J, Sweet S, Baxendale K, et al. Detection of *Giardia* and helminths in Western Europe at local K9 (canine) sites (DOGWALKS Study). *Parasit Vectors*. 2022;15(1):311. doi:10.1186/s13071-022-05440-2
6. Bourgoin G, Callait-Cardinal MP, Bouhsira E, et al. Prevalence of major digestive and respiratory helminths in dogs and cats in France: results of a multicenter study. *Parasit Vectors*. 2022;15(1):314. doi:10.1186/s13071-022-05368-7
7. Globokar Vrhovec M. *Retrospektive Analyse der parasitologischen Untersuchungs-ergebnisse eines privaten Untersuchungslabors: Intestinale, respiratorische und vektorübertragene Parasitosen bei Hunden und Katzen in Deutschland (2004–2006)*. Dissertation. Justus-Liebig-Universität Giessen; 2013.
8. Nijssse R, Mughini-Gras L, Wagenaar JA, Ploeger HW. Recurrent patent infections with *Toxocara canis* in household dogs older than six months: a prospective study. *Parasit Vectors*. 2016;9(1):531. doi:10.1186/s13071-016-1816-7
9. ESCCAP Modular Guide Series 01 Third Edition: Worm Control in Dogs and Cats [adapted from ESCCAP Guideline 01 Sixth Edition – May 2021: Worm Control in Dogs and Cats]. European Scientific Counsel Companion Animal Parasites; 2021. Accessed February 8, 2023. https://www.esccap.org/uploads/docs/uoayqf2a_0461_ESCCAP_MG1__English_20210518.pdf
10. Bowman DD, Hendrix CM, Lindsay DS, Barr SC. *Feline Clinical Parasitology*. Iowa State University Press; 2002.
11. Venco L, Valenti V, Genchi M, Grandi G. A Dog with pseudo-Addison disease associated with *Trichuris vulpis* infection. *J Parasitol Res*. 2011;2011:682039. doi:10.1155/2011/682039
12. Fahrion AS, Schnyder M, Wichert B, Deplazes P. *Toxocara* eggs shed by dogs and cats and their molecular and morphometric species-specific identification: is the finding of *T. cati* eggs shed by dogs of epidemiological relevance? *Vet Parasitol*. 2011;177(1–2):186–189. doi:10.1016/j.vetpar.2010.11.028
13. Nijssse R, Mughini-Gras L, Wagenaar JA, Ploeger HW. Coprophagy in dogs interferes in the diagnosis of parasitic infections by faecal examination. *Vet Parasitol*. 2014;204(3–4):304–309. doi:10.1016/j.vetpar.2014.05.019
14. Dryden MW, Payne PA, Ridley RK, Smith VE. Gastrointestinal parasites: the practice guide to accurate diagnosis and treatment. *Compend Contin Educ Vet*. 2006;28(suppl 8A):3–13.
15. Adolph C, Barnett S, Beall M, et al. Diagnostic strategies to reveal covert infections with intestinal helminths in dogs. *Vet Parasitol*. 2017;247:108–112. doi:10.1016/j.vetpar.2017.10.002
16. Hauck D, Raue K, Blazejak K, et al. Evaluation of a commercial coproantigen immunoassay for the detection of *Toxocara cati* and *Ancylostoma tubaeforme* in cats and *Uncinaria stenocephala* in dogs. *Parasitol Res*. 2023;122(1):185–194. doi:10.1007/s00436-022-07715-0
17. Kirkova Z, Dinev I. Morphological changes in the intestine of dogs, experimentally infected with *Trichuris vulpis*. *Bulg J Vet Med*. 2005;8(4):239–243.
18. Sweet S, Hegarty E, McCrann DJ, Coyne M, Kincaid D, Szlosek D. A 3-year retrospective analysis of canine intestinal parasites: fecal testing positivity by age, U.S. geographical region and reason for veterinary visit. *Parasit Vectors*. 2021;14(1):173. doi:10.1186/s13071-021-04678-6
19. Labuschagne M, Beugnet F, Rehbein S, Guillot J, Fourie J, Crafford D. Analysis of *Dipylidium caninum* tapeworms from dogs and cats, or their respective fleas – Part 1. Molecular characterization of *Dipylidium caninum*: genetic analysis supporting two distinct species adapted to dogs and cats. Analyse des ténias *Dipylidium caninum* des chiens et des chats, ou de leurs puces respectives – Partie 1. Caractérisation moléculaire de *Dipylidium caninum* : analyse génétique soutenant deux espèces distinctes adaptées aux chiens et aux chats. *Parasite*. 2018;25:30. doi:10.1051/parasite/2018028

References (cont.)

20. Beugnet F, Labuschagne M, Vos C, Crafford D, Fourie J. Analysis of *Dipylidium caninum* tapeworms from dogs and cats, or their respective fleas – Part 2. Distinct canine and feline host association with two different *Dipylidium caninum* genotypes. Analyse des ténias *Dipylidium caninum* des chiens et des chats, ou de leurs puces respectives – Partie 2. Association distincte des hôtes canins et félins avec deux génotypes différents de *Dipylidium caninum*. *Parasite*. 2018;25:31. doi:10.1051/parasite/2018029
21. Beall M, Tyrrell P, Bezold T, Hanna R, Hanscom J, Rogosienski O, Elsemore D. *Dipylidium caninum* coproantigen detection by immunoassay agrees with nucleic acid detection by PCR in dogs with experimental and natural infections. Paper presented at: American Association of Veterinary Parasitologists 67th Annual Meeting; June 26, 2022; Snowbird, UT.
22. Elsemore D. Detection of *Dipylidium caninum* coproantigen in experimental and natural infections [AAVP Abstract 23]. Paper presented at: American Association of Veterinary Parasitologists 67th Annual Meeting; June 26, 2022; Snowbird, UT.
23. Elsemore DA, Geng J, Cote J, Hanna R, Lucio-Forster A, Bowman DD. Enzyme-linked immunosorbent assays for coproantigen detection of *Ancylostoma caninum* and *Toxocara canis* in dogs and *Toxocara cati* in cats. *J Vet Diagn Invest*. 2017;29(5):645–653. doi:10.1177/1040638717706098
24. Elsemore DA, Geng J, Flynn L, Cruthers L, Lucio-Forster A, Bowman DD. Enzyme-linked immunosorbent assay for coproantigen detection of *Trichuris vulpis* in dogs. *J Vet Diagn Invest*. 2014;26(3):404–411.

The information contained herein is intended to provide general guidance only. As with any diagnosis or treatment, you should use clinical discretion with each patient based on a complete evaluation of the patient, including history, physical presentation and complete laboratory data. With respect to any drug therapy or monitoring program, you should refer to product inserts for a complete description of dosages, indications, interactions and cautions.